International Journal of Biomedical Research

ISSN: 0976-9633 (Online)
Journal DOI:10.7439/ijbr
CODEN:IJBRFA

Research Article

Pitfalls in the Diagnosis of Fine Needle Aspiration Cytology of the Thyroid

Prema Saldanha and Huzaifa N Tak*

Department of Pathology, Yenepoya Medical College, Deralkatte, Mangalore-575018 Karnataka

***Correspondence Info:**
Dr. Huzaifa N Tak
Department of Pathology,
Yenepoya Medical College,
Deralakatte, Mangalore, Karnataka - 575018.
E-mail: huzy88@gmail.com

Abstract

Objective: Fine Needle Aspiration Cytology (FNAC) of the thyroid is a reliable, simple, minimally invasive, cost effective procedure with a high sensitivity, specificity and diagnostic accuracy. It is commonly used for the pre-operative assessment of thyroid lesions and as a guide to management. The aim of the study was to assess the accuracy of fine needle aspiration of the thyroid and critically evaluate the cases which showed discordance between cytology and histopathology.

Material & Method: A total of 522 patients with thyroid swelling were aspirated during a four-year study period. Cases showing cytological and histological disparity were re-evaluated for the detection of possible causes of discrepancy.

Results: In our study, cytohistological concordance was achieved in 97.8% of the cases. The sensitivity was found to be 72%, specificity 93.5%, positive predictive value was 78.3%, negative predictive value was 91.1% and total accuracy was 97.8%. False positives accounted for 5.4% and false negatives for 7.6% of the cases. Suboptimal material, lack of extensive sampling and absence of the characteristic nuclear features causing under diagnoses of papillary carcinoma were recognized as common pitfalls. Too much emphasis on cellularity and architectural pattern led to the erroneous false positive diagnoses of malignancy. Too much stress on only one nuclear criteria or focal nature of the features can lead to a misdiagnosis of papillary carcinoma.

Conclusion: Strict adherence to adequacy criterion and extensive sampling are of paramount importance in reducing false positive and negative cases.

Keywords: Thyroid FNAC, pitfalls

1. Introduction

Fine Needle Aspiration Cytology (FNAC) of the thyroid is a reliable, simple, minimally invasive, cost effective procedure with a high sensitivity, specificity and diagnostic accuracy. It has been used routinely as a useful and indispensable tool in the pre-operative diagnosis of thyroid lesions. FNAC has shown to be able to categorise many lesions and hence guide therapeutic protocols.[1] Like any other diagnostic procedure, FNAC has its limitations. There is some "grey zone" of thyroid cytology, where the diagnostic efficacy declines sharply rendering it difficult to exactly categorize the lesion resulting in discrepancy especially between benign and malignant lesions. This is due to the overlapping of cytological features between the lesions.[1,2]

The aim of the study was to assess the accuracy of fine needle aspiration of the thyroid and critically evaluate the cytohistologically discordant cases.

2. Material& Method

This is a retrospective study of all cases of thyroid FNAC which were donefrom May 2010 to April 2014 (four years). The aspiration was done using a 22G needle and a 10ml syringe. In cases of haemorrhagic samples, the aspiration was repeated using a 23G needle. In cases with small thyroid nodules, ultrasonographic guidance was utilised. The smears were fixed in absolute methanol and stained with Papanicolaou stain. Relevant clinical details, thyroid function test results and ultrasonography findings were recorded.

The FNAC findings were reported according to the Bethesda classification which includes six categories - Nondiagnostic or Unsatisfactory, Benign, Atypia of Undetermined Significance or Follicular Lesion of Undetermined Significance, Follicular Neoplasm or Suspicious for a Follicular Neoplasm, Suspicious for Malignancy and Malignant.[3] Cases showing cytohistologic disparity were re-evaluated for the detection of possible causes of discrepancy. This did not include cases where the material was inadequate on FNAC, but surgery was performed.

3. Results

A total of 522 patients with thyroid swelling were aspirated during the four-year study period. There were 467 female and 55 male patients the ages ranging from 11 to 75 years. The lesions in the various categories were Nondiagnostic or Unsatisfactory – 22%, Benign- 69.5%, Atypia of Undetermined Significance or Follicular Lesion of Undetermined Significance – 0.1%, Follicular Neoplasm or Suspicious for a Follicular Neoplasm – 3.4%, Suspicious for Malignancy – 2% and Malignant – 2.5%.

In our study, cytohistological concordance was achieved in 97.8% of the cases. The sensitivity was found to be 72%, specificity 93.5%, positive predictive value was 78.3%, negative predictive value was 91.1% and total accuracy was 97.8%. False positives accounted for 5.4% and false negatives for 7.6%% of the cases. Cases with discrepancy in the cytology and histopathology reports are shown in Table 1.

Table 1: showing the cases with cytological and histopathological discordance

Cytological diagnosis	Histopathological diagnosis	Number of cases	Comments
Follicular neoplasm	Nodular goitre Follicular variant of PTC WDT-UMP*	4 4 1	Emphasis on cellularity and focal microfollicular pattern Nuclear features of PTC not seen Nuclear features of PTC not seen
Nodular goitre	Papillary carcinoma-classical Papillary carcinoma -micropapillary variant Follicular adenoma	3 1 3	Inadequate sampling Too small to be picked up on FNAC Low cellularity, absence of architectural pattern and overlooking of focal overlapping
	Follicular carcinoma (well-differentiated)	1	Low cellularity , absence of architectural pattern and overlooking of focal overlapping
	Hurthle cell adenoma Hashimoto thyroiditis	1 4	Few Hurthle cells Colloid and low cellularity
Suspicious for papillary ca	Nodular goitre	1	Papillaroid fragments "chewing-gum" like colloid

*Well-differentiated tumour- uncertain malignant potential (WDT-UMP)

4. Discussion

An adequate specimen of good technical quality is considered diagnostic or satisfactory and in general may be "benign," "suspicious," or "malignant."A clinical solitary nodule usually favours a neoplastic process. The various cases in the Bethesda categories are similar to those found in other studies (Table 2)

Table 2 showing the percentage of cases in the different Bethesda categories

	Category I	Category II	Category III	Category IV	Category V	Category VI
Kini SR[2]	20	60-70	-	10-15	11-21	1-18
Gharib H[4]	17	69	-	-	10-30	1-10
Bukari[5]	15.6	86.4	18	4.8	6	13.2
Present study	22	69.5	0.1	3.4	2	2.5

False positive cases can be due to interpretive or sampling errors. Hashimoto's thyroiditis is a common cause of false-positive cytology. Misclassification of follicular and Hürthle cell adenomas as papillary carcinomas account for other errors. FNA biopsy of thyroid lymphomas may produce lymphocytes that can be interpreted as Hashimoto's thyroiditis, accounting for a false-negative diagnosis.[4]

False negative results may occur because of sampling error or cytological features which are overlapping. They are a cause for great concern because they indicate the potential to miss a malignant lesion. Besides, since only a small percentage of patients with benign diagnosis on FNAC undergo surgery, it is difficult to establish the true frequency of false negative cases.[4,6]

Inadequate or improper sampling accounts for some false-negative cases. For example, nodules smaller than 1 cm may be too small for accurate needle placement, and nodules larger than 4 cm are too large to allow proper sampling from all areas, thereby increasing the likelihood of misdiagnosis.[4] Increasing the number of passes [1,7] and use of ultrasonographic guidance minimises these problems.[1,2,4,6,7,8,9] Four reasons for these low sensitivities have been identified: tumours missed at aspiration, microscopic misinterpretations, diagnoses of cellular atypia and indeterminate diagnoses.[5] The sensitivity and specificity in various studies [1,2,5,6,8,10,11,12] varied from 57.14-93.4%and 74.9-94.2% respectively. The sensitivity of 72% and specificity of 93.5% found in our study correlated with those of these studies.

Follicular neoplasm (FN) may be benign (adenoma) or malignant (carcinoma).The distinction can be made with confidence only on histopathology by demonstrating capsular or vascular invasion.[1,2,6,7,10] While an adenoma may be "hot" or "cold" on radio-isotope scan, carcinoma is usually "cold".[5]In our centre the diagnosis of only follicular neoplasm is made on FNAC and histopathology is advised to demonstrate invasion if any. Nuclear atypia does not help to diagnose a carcinoma as some nuclear atypia can be seen in an atypical adenoma which is benign.[1,2,6,7,10] Smears in FN are cellular and are usually devoid of colloid. The smears show many uniform-sized follicular cell clusters and microfollicles (Figure1). This repetitive smear pattern is in contrast to the variable cell pattern seen in colloid/nodular goitre.[1,2,6,7,8,10,12,13]

The hyperplastic/dominant noduleis often a diagnostic problem, as there is a considerable overlap in the cytological features.Cytological differentiation between follicular neoplasm and adenomatous goitre is not only confusing, sometimes seems very difficult.As a general rule, smears from a non-neoplastic adenomatous nodule show less cells and more colloid than those from follicular neoplasm. Presence of colloid and hemosiderin-laden macrophages are in favour of colloid goitre. However, a macrofollicular adenoma may show colloid and follicular hyperplasia in nodular goitre may show scant colloid, high cellularity and acinar pattern.

Follicular neoplasms show syncytial groups, nuclear crowding and overlapping, which may be missed if it is focal. (Figure 1) .In rare cases with confusing cellular smears , the presence of dispersed rather than tightly cohesive follicular cells is in favour of non-neoplastic adenomatous nodule.[1,2,6,7,8,10,12,13].

Figure1: (a)Smear showing a cluster of uniform follicular epithelial cells with mild overlapping (Pap,x400). (b)Histopathology of the same case showed a neoplasm diagnosed as follicular adenoma (H and E,x400).

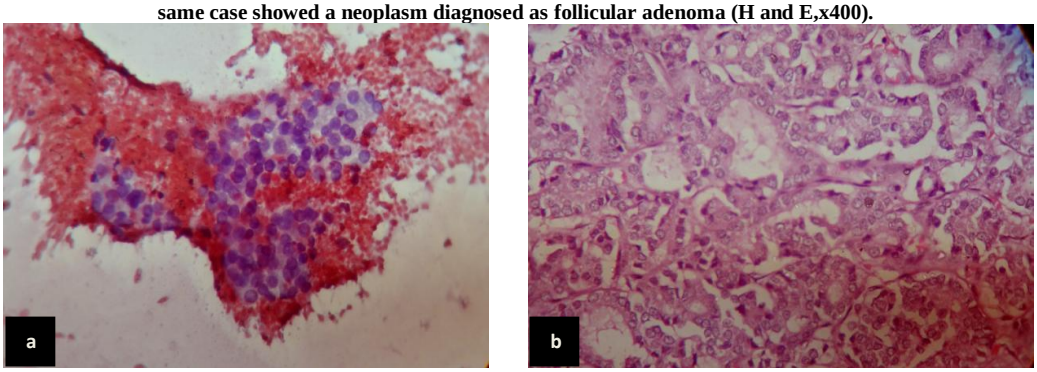

Ultrasonographic examination may demonstrate multinodularity.[1,2,6,7,8,9]Also, thyroid scintigram may solve this problem, where neoplastic nodules appear as cold nodules.[7] Some of the cases in our study were diagnosed as follicular neoplasm due to the high cellularity and scant colloid with emphasis on the focal microfollicular pattern. On histopathology, these cases were found to be nodular goitre.

As in follicular neoplasms, aspirates of Hürthle cell adenomas cannot be differentiated from Hurthle cell carcinomas. Cytomorphologicfeatures in a Hurthle cell nodules which are found to beuseful for diagnosingHurthle cell neoplasm (HCN) area non-macro follicular architecture, absence ofchronic inflammatory cells, absence of background colloid, transgressing blood vessels, more than 90% Hurthle cells, and very few single cells. When used in combination, the first four of these cytological features are found to be the most highly predictive of HCN[14,15]

Papillary thyroid carcinoma (PTC) is the most common malignant tumour of the thyroid. Smears may show syncytial aggregates with nuclear crowding and overlapping and papillary tissue fragments. Its classic nuclear features are enlarged ovoid/elongated strikingly pale nuclei, finely granular powdery chromatin, inconspicuous eccentric nucleoli, crinkled nuclear membranes, chromatin clearing, intranuclear grooves/ creases/ ridges/ bars and intranuclear cytoplasmic inclusions (INCI). "Chewing gum" colloid appearing as strand or chunks of dense, dark blue colloid and psammoma bodies resembling concentric lamellated calcified structure are seen in some cases and aid in the diagnosis.[1,2,7,16]The presence of three out of the following five features facilitate the diagnosis – papillae, psammoma bodies, nuclear grooves, INCI and fine powdery chromatin. The presence of grooves and INCI in high frequency is most dependable.[1]

Too much emphasis on papillary architecture and intranuclear inclusions can lead to over diagnosis. The minimal criteria for cytodiagnosis of papillary carcinoma include, a syncytial tissue fragment, typical nuclear features i.e. pale enlarged nuclei with fine dusty and powdery chromatin; chromatingroove, bar or ridge; single or multiple micro-and/or macro nucleoli; and intranuclear cytoplasmic inclusion. Although these typical nuclear alterations help to define papillary carcinoma, none of these are diagnostic of papillary carcinoma in isolation or low frequency.[16]

Emphasis on cellularity and architectural patterns without cytomorphology of papillary carcinoma and too much stress on only one nuclear criterion can lead to a misdiagnosis of PTC.[6,16] Smears can be misdiagnosed as showing cellular atypia when papillary formations are missing and only one or two of the other cellular criteria are evident.[6,16] INCI are seen in upto 90% of the cases in about 5% of the cells (10% if examined under oil immersion). Artefacts such as superimposed air bubbles or fat droplets can mimic INCI.[1]

Air-drying artifact of thyroid FNAC specimens can lead to enlargement and marked hypochromasia of the follicular cells. This chromatin change in some cases may assume a circumferential shape with sharp borders and mimic intranuclear inclusions of papillary carcinoma. This pseudoclearing of the thyroid follicular cells is more pronounced in specimens containing large amounts of peripheral blood, which hinders proper fixation of smears. This can be avoided by using a needle with a thinner gauge and limiting the number of passes.[16]

In chronic lymphocytic thyroiditis, the follicular epithelium adjacent to the lymphoid aggregates or infiltrated by lymphocytes can show atypical nuclear changes that can be mistaken for foci of PTC. These changes include nuclear enlargement, nuclear membrane irregularities, nuclear chromatin clearing, nuclear membrane thickening, nuclear grooves, and occasional intranuclear inclusions. The follicular epithelium can appear as large syncytial fragments and papillary clusters.[16]

Strict criteria for recognition of the longitudinal grooves are defined- grooves running the length of the nucleus and present in > 20% of the cells.[1]A small number of grooves can be [found in nonneoplastic thyroid lesions, nonpapillary neoplasms, and nonthyroid neoplasms especially those in tissues in the vicinity of the thyroid (paragangliomas and parathyroid neoplasms).[1]

Misinterpretation of partly degenerated non-neoplastic follicular cells, focal papillaroid architecture, and presence of intranuclear inclusions are probably the causes of error in some cases. Multiple samples collected from different parts of the lesion could help in making a proper diagnosis. For the cytodiagnosis of papillary thyroid cancer, the important features suggested are intranuclear cytoplasmic inclusions, dense metaplastic cytoplasm, and papillae with a distinct anatomical border.[16]

Sampling errors (Figure 2),suboptimal material, cystic change in the carcinoma with aspiration of only cyst fluid and absence of the characteristic architecture and nuclear features (Figure 3) can also cause underdiagnoses of papillary carcinoma.[6,16,17,18,19,20,21] Increasing the number of passes during FNAC [1,7] and use of ultrasonographic guidance to detect suspicious nodules minimises the sampling problems.[1,2,4,6,7,8,9]

In conclusion, strict adherence to adequacy criterion and extensive sampling are of paramount importance in reducing discrepant cases.

Figure 2: (a) Smear shows a cluster of uniform follicular epithelial cells .This case was diagnosed as nodular goitre (Pap x100). (b)Histopathological examination of the same case showed a focus of papillary carcinoma[micropapillary carcinoma (H and E x 400)]

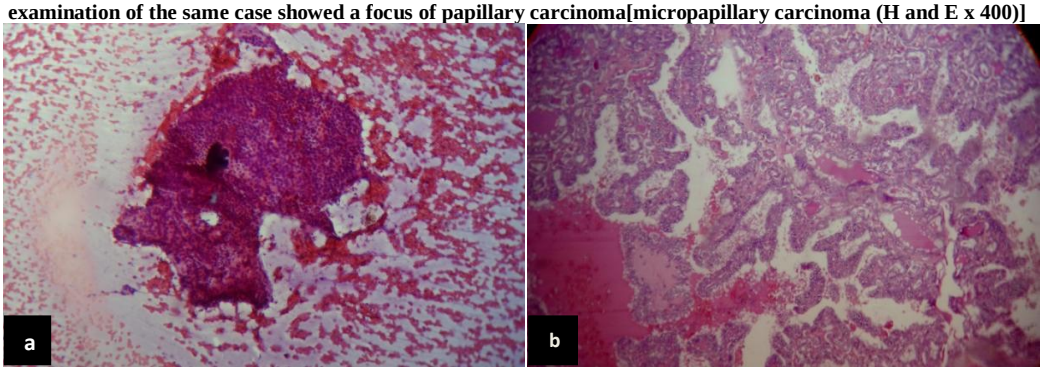

Figure 3 :(a) Smear shows a cluster of follicular epithelial cells with mild anisonucleosis .Nuclear features of papillary carcinoma were not seen (Pap x400). (b) Histopathology of the same case showing papillary carcinoma –solid variant (H and E x400)

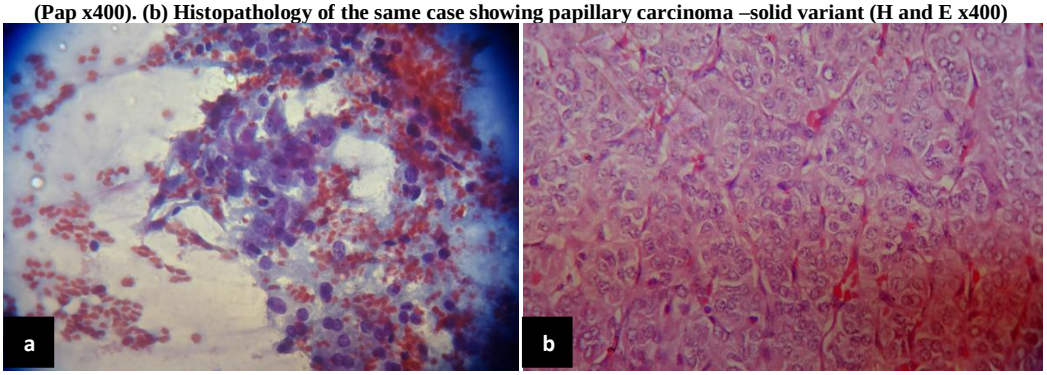

References

1. Jayaram G, Orell SR. Thyroid. In: Orell SR, Sterett GF, eds. Orell & Sterrett's Fine Needle Aspiration Cytology. Churchill Livingstone, Elsevier, China, 2012: 118-55.
2. Kini SR. Thyroid Cytopathology. An Atlas and Text. Wolters Kluver/ Lippincott Williams & Wilkins, 2008.
3. Ali SZ, Cibas ES. The Bethesda System for Reporting Thyroid Cytopathology. Springer, London, 2010.
4. GharibH. Fine-Needle Aspiration Biopsy of the Thyroid Gland. http://www.thyroidmanager.org/wp-content/uploads/chapters/fine-needle-aspiration-biopsy-of-the-thyroid-gland.pdf.
5. Bukhari MH, Khan AA, Niazi S, Arshad M, Akhtar ZM. Better Thyroid Cytopathology Reporting System May Increase the Clinical Management and Patients Outcome. *J Cytol Histol* 2012; 3:158.http://dx.doi.org/10.4172/2157-7099.1000158.
6. Pandey P, Dixit A, Mahajan NC. Fine-needle aspiration of the thyroid: A cytohistologic correlation with critical evaluation of discordant cases. *Thyroid Res Pract* 2012; 9:32-9.
7. Jayaram G. AtlasAnd Text of Thyroid Cytology. Arya Publications, New Delhi, 2006.
8. Sinna EA, Ezzat N. Diagnostic accuracy of fine needle aspiration cytology in thyroid lesions. *J Egypt Natl Can Inst* 2012; 24: 63-70.
9. Poller DN, E. B. Stelow EB, Yiangou C. Thyroid FNAC cytology: can we do it better? *Cytopathology* 2008; 19:4-10.
10. Akerman M, Tennvall J, Biörklund A, Martensson H, Möller T. Sensitivity and specificity of fine needle aspiration cytology in the diagnosis of tumors of the thyroid gland. *Acta Cytol* 1985; 29: 850-5.
11. Bhatta S, Makaju R, Mohammad A. Role of fine needle aspiration cytology in the diagnosis of thyroid lesions. *J of Pathol Nepal* 2012; 2: 186-8.
12. Ergete W, Abebe D. Discordance Rate between Thyroid Fine Needle Aspiration Cytology and Histopathologic Diagnosis. *Ethiop J Health Dev* 2002; 16: 227-31.
13. Somma J, Schlecht NF, Fink D, Khader SN, Smith RV, Cajigas A. Thyroid Fine Needle Aspiration Cytology. Follicular Lesions and the Gray Zone. *Acta Cytol* 2010; 54: 123–31.
14. Elliott DD, Pitman MB, Bloom L, Faquin WC. Fine-Needle Aspiration Biopsy of Hurthle Cell Lesions of the Thyroid Gland. A Cytomorphologic Study of 139 Cases with Statistical Analysis. *Cancer Cytopathology* 2006; 108: 102-9.
15. Kini SR, Miller JM, Hamburger JI. Cytopathology of Hurthle cell lesions of the thyroid gland by fine needle aspiration. *Acta Cytol* 1981; 25:647-52.
16. Baloch ZW, Virginia A. LiVolsiVACytologic and Architectural Mimics of Papillary Thyroid Carcinoma. Diagnostic Challenges in Fine-Needle Aspiration and Surgical Pathology Specimens. *Am J Clin Pathol* 2006; 125: S135-S144.
17. Raab SS, Vrbin CM, Grzybicki DM, Sudilovsky D, Balassanian R, Zarbo RJ, *et al*. Errors in Thyroid Gland Fine-Needle Aspiration. *Am J Clin Pathol* 2006; 125: 873-82.
18. Mahar SA, Husain A, Islam N. Fine Needle Aspiration Cytology of Thyroid Nodule: Diagnostic Accuracy and Pitfalls. *J Ayub Med Coll Abbottabad*. 2006; 18:26-9.
19. Caraway NP1, Sneige N, Samaan NA. Diagnostic pitfalls in thyroid fine-needle aspiration: A review of 394 cases. *Diagn Cytopathol*. 1993; 9: 345-50.
20. Hamburger JI, Husain M, Nishiyama R, Nunez C, Solomon D. Increasing the accuracy of fine-needle biopsy for thyroid nodules. *Arch Pathol Lab Med*. 1989; 113:1035-41.
21. Hsu C1, Boey J. Diagnostic pitfalls in the fine needle aspiration of thyroid nodules. A study of 555 cases in Chinese patients. *Acta Cytol*. 1987; 31:699-704.