

Research Article

Morphometry of adult humerus bone in Moradabad region

Rahul Rai^{*1} and Maheshwar Chawla²

¹Department of Anatomy, Teerthanker Mahaveer Medical College & Research Center, Moradabad, Uttar Pradesh (244102, India)

²Department of Anatomy, Goldfield Institute of Medical Sciences & Research, Chhainsa, Ballabgarh, Faridabad-121004 (Haryana) India

***Correspondence Info:**

Dr. Rahul Rai

Department of Anatomy,

Teerthanker Mahaveer Medical College & Research Center, Moradabad, Uttar Pradesh, India

Email: rahulrai58@gmail.com

Abstract

Background: Morphometric examination of upper and lower limb can be useful to medical anthropologists, archaeologists, forensic experts and medico legal studies. The aim of our study was to determine length of humerus and humerus segment.

Materials and methods: Total of 80 humerus (40 right and 40 left) were collected from the department of Anatomy, Teerthanker Mahaveer Medical College and Research Center and studied. Results were expressed as mean±sd. The parameters measured were maximum length of humerus (MHH), distance between articular segment of humerus head and greater tuberosity (H1), caput humeri and collum anatomicum (H2), proximal and distal point of olecranon fossa (H3), distal point of olecranon fossa and trochlea humeri (H4) and proximal edge of olecranon fossa and proximal point of trochlea humeri (H5).

Results: Mean MHH, H1, H2, H3, H4 and H5 were found to be 302±2.14mm, 6.4±1.3mm, 39.3±5.4mm, 27.4±2.4mm, 26.1±2.1 and 34.5±6 on the right and 297.5±2.1mm, 6.5±1.3mm, 39.2±4.8mm, 27.5±2.6mm, 22.1±2.3 and 32.6±3.5mm on the left humerus respectively

Conclusion: Our study supplies the mean values of the different morphometric measurements from the humerus that may be useful in forensic, anatomic and archeological cases.

Keywords: Humerus, olecranon fossa, trochlea, morphometry

1. Introduction

Almost all bones of the human skeleton show some degree of sexual dimorphism. The cross-sectional area of long bones is greater in males compared to females and this is tough to reflect more rapid periosteal bone growth in boys¹. But it is unclear whether these findings reflect gender differences in bone size or shape; previous studies tried to confirm the factors that affect the long bone dimensions and to explain the phenomenon of the different lengths between the right and left humerus^{2,3}. Anthropometric techniques have been commonly used to estimate stature and bone length from the *skeletal* remains and unknown body parts by anthropologists, medical scientists and anatomists for over a hundred years^{4,5,6}. In many situations when the full length of long bones may not be available some methods can be used, as per as studies of Wright⁷ and Mysorekar⁸.

In the absence of pelvis and cranium, morphometric analysis is frequently carried out on the remains of the long bones of the individual in anthropology and forensic science investigations^{9,10,11}. Muller was first to define 5 segments for the humerus using the margins of articular surfaces and key points of muscle attachment⁷. This segment measurement is very helpful for determining the humerus length¹². It is also very important for anatomic and forensic science and helps the investigator to define the identity of a skeleton. These data give evidences to indicate the characteristic features of a population for archaeological materials^{7,13,14}. The humerus offers important advantages over other long bones in that its entire outline can readily be traced on total body X-ray absorptiometry (DXA) images, and its shape can be modeled as a cylinder with reasonable accuracy¹⁵.

Therefore the present study was conducted to determine the mean values of humerus segments in Moradabad region, which may be useful to the anatomist and forensic investigators.

2. Materials and Methods

80 dry adult humerus (40 right and 40 left) were collected for the study from the Department of Anatomy, Teerthanker Mahaveer Medical College and Research Center. Bones in poor conditions or partly damaged were not considered. The lengths of the segments of humerus were measured with the caliper. Six measurements were taken and were as follows:

- MHH: Maximum length of the humerus: the distance between the most proximal point of the caput humeri to the most distal point of the trochlea of humerus (A-F),
- H1: The distances between the articular segment of the humeral head and the greater tuberosity (A-B),
- H2: The distance between proximal point of caput humerus and collum anatomicum of humerus (A-C),
- H3: The distance between proximal and distal point of olecranon fossa of humerus (D-E),
- H4: Mean distance between distal part of olecranon process and trochlea of humerus (E-F) and
- H5: The distance between proximal edge of olecranon fossa and proximal part of trochlea of humerus. (D-F).

From these measurements mean and standard deviations were calculated. Segments of humerus measured are shown in figure (1)¹⁶.

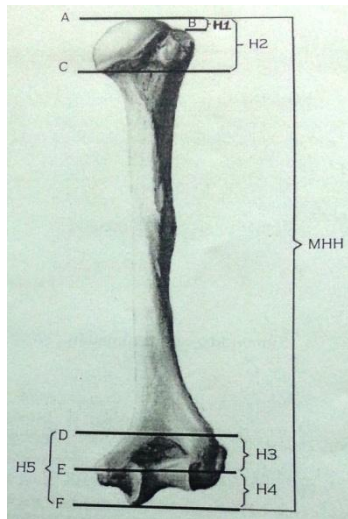


Figure 1: Segments of humerus

3. Result

The mean values of different segments of humerus (H1, H2, H3, H4 and H5) and maximum length of humerus (MHH) are shown in millimeter (mm) in the table 1. The results were calculated in terms of mean ± sd

Table 1: Maximum length of humerus

SN	Parameter	Right humerus	Left humerus
1	MHH	302±21.4	297.5±21.1
2	H1	6.4±1.3	6.5±1.3
3	H2	39.3±5.4	39.2±4.8
4	H3	27.4±2.4	27.5±2.6
5	H4	26.1±2.9	22.1±2.3
6	H5	34.5±3.6	32.6±3.5

The mean maximum height of the humerus (MHH: mean distance between caput humerus and trochlea of humerus A-F) was 302±21.4 mm in the right side and 297.5±21.1 mm in the left side. The mean distance (H1) from caput humeri (A) to greater tuberosity of humerus (B) was 6.4±1.3 and 6.5±1.3 on right and left side respectively. Similarly, the distance (H2) from caput humeri (A) to collum anatomicum (C) was 39.3±5.4mm on right and 39.2±4.8mm on left side. The other segments measured were the distances from the proximal margin of olecranon fossa (D) to distal margin of olecranon fossa (E) and trochlea (F). The mean distances were 27.4±2.4mm (H3:D-E) and 34.5±3.6mm (H5: D-F) on the right side and 27.5±2.6mm (H3:D-E) and 32.6±3.5mm (H5: D-F) on the left side respectively. The final measurement was taken between the distal margin of olecranon fossa (E) and trochlea (F) (H4: E-F). It was 26.1±2.9mm on right humerus and 22.1±2.3mm on left humerus.

4. Discussion

The humerus is the longest and largest bone of the upper limb and it is very important to identify the humeral length from the segmental measurements. In forensic anthropology, a method for estimating height based on the distances of segments of long bones is important.¹⁶ In our study, the mean values of the maximum humerus length (MHH) of the adult humerus were found to be 302.6±21.4 & 297.5±21.1 mm on the right and left side respectively. Our results were similar and comparable to Simesh *et al*¹⁷, Turkish¹⁶ and Spanish population¹² but there were significant differences with Bulgarian and Maya populations¹². In a study of the Portuguese population made with fresh bones the mean values of total humerus length were greater than our dry bones. It was reported over 100 years ago that dry bones are slightly smaller than fresh ones and this difference has been established as approximately 2 mm¹⁸.

The mean distance (H2) from caput humeri to collum anatomicum was 39.3±5.4mm on right and 39.2±4.8mm on left side. This was comparable to that of SD Desai *et al* who found the distance to be 39.6±6.3mm on right and 39.1±6.1mm on left side respectively¹⁹. On comparison with Turkish population, it (H2) was 41.0 ± 5.1 mm and 40.9 ± 3.9 mm on the right and left side respectively¹⁶. Similarly, in a study from Guatemala the distance was 32.8 ± 2.7 mm and it is therefore evident that there are differences in the values obtained as against previous studies^{7,18,20,21}.

In anatomical studies it was reported that the highest point on the articular segment of the humeral head is found 6 to 8 mm above from the most proximal point of the greater tuberosity^{22,23}. This relationship is important because the relative height of the greater tuberosity determines the amount of subacromial clearance as the arm is elevated. Moreover in clinical assessment this point is important for the treatment of isolated greater tuberosity fractures which extends along the epiphysal lines of the proximal humerus and its segments, causing their displacement to various degrees^{16,17}. In our study we found this distance (H1:distance between articular segment of humeral head and the greater tuberosity) on the right humerus to be 6.4 ± 1.3 mm and 6.5 ± 1.3 mm on left humerus. Our mean values are similar to other anatomic studies^{16,23}.

Olecranon fractures occur in 10% of all upper extremity lesions. The lesion might be the result of indirect or direct trauma, especially forced hyperextension of the elbow joint²⁴. The distance between proximal and distal margin of olecranon fossa (H3) according to our study was 27.4±2.4mm on right and 27.5±2.6mm on left side. In the study of SD Desai *et al*, H3 was 38.3±1.9mm on right and 39.7±2.5mm on left side¹⁹ whereas in Turkish population it was found to be 24.2 ± 2.07 mm and 23.9 ± 2.63 mm on the right and left humerus respectively¹⁶, but Simesh *et al* observed H3 to be 20.14 ± 3.43 mm & 19.06 ± 2.92mm on right and left humerus respectively¹⁷. In an archeological study the distance between the proximal and distal margin of olecranon fossa was identified as 20.2 ± 1.9 mm for females and for males as 20.3 ± 1.3 mm²⁵. In another study the distance (H4) between the distal margin of the olecranon fossa and trochlea was 14.2 ± 1.8 mm on the right humerus for males⁷ whereas in our study this was found to be 26.1±2.9mm on right humerus and 22.1±2.3mm on left humerus respectively. Our values were more than that of Turkish (20.0±2.2 mm and 19.7±2.5mm) population¹⁶ but the mean distance H4 obtained in the study of SD Desai *et al*¹⁹ and Simesh *et al*¹⁷ were less than that of Turkish population.

The distal humerus has a unique and special anatomy and it freely articulates with the bones of the forearm, the radius and ulna¹⁶ and fractures involving it may pose several reconstructive problems and complications¹⁷. Therefore these fractures are difficult for orthopedic surgeons to treat. Various implants are available for the diverse fracture patterns observed in the distal humerus and these plates are contoured specifically for the anatomy of this region. Anatomically based precontoured condylar plate systems that can assist with fracture reduction have been developed²⁶. When we assessed the distance from the proximal margin of the olecranon fossa to the distal trochlea (H5), it was found to be 34.5 ± 3.6 mm (right) and 32.6 ± 3.5 mm (left). These values were similar to the results of Somesh *et al*¹⁷ but our values were more than that obtained in the study of SD desai *et al*¹⁹ and much less than that of the Turkish population¹⁶.

5. Conclusion

Knowledge of the morphometric values of humerus segments is important in forensic, anatomical and archeological cases in order to identify unknown bodies and stature. It is also helpful for the clinician in the treatment of proximal and distal humerus fractures. Therefore our study supplies the data of the different morphometric measurements from the humerus.

References

1. Williams PL, Warwick R, Dyson M, and Bannister LH. The humerus. In Gray's Anatomy, 37th edition, Edinburgh, Churchill Livingstone, 1989: 406.
2. Gennadis G. Textbook of Regional Anatomy. 1st edition, Antoniadis Publisher, Athens, 1858: 270- 271.
3. Vettivel S, Selvaraj KG, Chandi SM, Indrasingh I and Chandi G. Intertubercular Sulcus of the Humerus as an Indicator of Handedness and Humeral Length. *Clin. Anatomy*. 1995; 8: 44-50.
4. Beddoe J. On the stature of the older races of England, as estimated from the long bones. *J R Anthropol Inst*. 17: 202- 207, 1887- 1888.
5. Zaslán A, Ubcán MY, Zaslán U *et al*. Estimation of stature from body parts. *Forensic Sci Int*. 2003, 3501: 1- 6.
6. Pearson K. Mathematical contribution to the theory of evaluation. V. On the reconstruction of the stature of prehistoric races. *Philos Trans R Soc Lond*. 1899; 192: 169- 244.
7. Wright LE, Vasquez MA. Estimation the length of incomplete long bones: Forensic standards from Guatemala. *Am J Phys Anthropol*. 2003;120: 233- 251
8. Mysorekar VL, Verma PK, Mandedkar AN, Sarmat TC. Estimation of stature from parts of bones--lower end of femur and upper end of radius. *Med. Sci. Law*. 1980; 20(4):283-6.
9. Nath S. & Badkur P. Reconstruction of stature from long bone lengths. *Int. J. Osteoarchaeol*. 2002; 1:109-14.
10. Beddoe, J. On the stature of the older races of England, as estimated from the long bones. *J. Anthropol. Inst. Great Brit*. 1888; 17:202-7.
11. Petersen HC. On the accuracy of estimating living stature from skeletal length in the grave and by linear regression. *Int. J. Osteoarchaeol*. 2005; 15:106-14.
12. Munoz JI, Iglesias ML, Penaranda JMS. Stature estimation from radiographically determined long bone length in a Spanish population sample. *Forensic Sci Int*. 2001; 46: 363- 366.
13. Koshy S, Vettivel S, Selvaraj KG. Estimation of length of calcaneum and talus from their bony markers. *Forensic Sci Int*. 2002; 129: 200- 204.
14. Mall G, Hubig M. A sex determination and estimation of stature from the long bones of the arm. *Forensic Sci Int*. 2001; 117: 23-30.
15. White TD and Folkens PA. The Human Bone Manual. 1st edition, Elsevier Academic Press, New York. 2005: 52-54.
16. Akman SD, Karakas P, Bozkir MG. The Morphometric Measurements of Humerus Segments. *Turk J Med Sci*. 36 (2006) 81-85
17. Somesh MS, Prabhu LV, Shilpa K, Pai MM, Ashwin Krishnamurthy & Murlimanju B. Morphometric Study of the Humerus Segments in Indian Population. *Int. J. Morphol*. 2011; 9(4):1174-1180.
18. De Mendon. Estimation of height from the length of long bones in a Portuguese adult population. *Am J Phys Anthropol*. 2000; 112: 39-48.
19. Desai SD, Shaik HS. A Morphometric Study of Humerus Segments. *J. Pharm. Sci. & Res*. 2012; 4(10), 1943 – 1945.
20. Hertzog KP, Garn SM, & Hempy HO. 3rd. Partitioning of the effects of secular trend and aging on adult stature. *Am. J. Phys. Anthropol*. 1969; 31(1):111-5.
21. Zverev Y. & Chisi J. Estimating height from arm spans measurement in Malawian children. *Coll. Antropol*. 2005 29(2):469-73.
22. Lannotti JP, Gabriel JP, Schneck SL undred and forty shoulders. *J Bone Joint Surg Am*. 1992; 74: 491-500.
23. Green A. & Izzi J. Isolated fractures of the greater tuberosity of the proximal humerus. *J. Shoulder Elbow Surg*. 2003; 12(6):641-9.
24. Rommens PM, Kchle R, Schneider RU *et al*. Olecranon fractures in adults: factors influencing outcome. *Injury Int J Care Injured*. 2004; 34: 1149- 1157.
25. Churchill SE, Smith FH. A modern human humerus from the early Aurignacian of Vogelherdh.le (Stetten, Germany) *Am J Phys Anthropol*. 2000; 112: 251- 273.
26. Jupiter JB, Mehne DK. Fracture of distal humerus. *Orthopedics*. 1992; 15: 825-33.